

Dieter H. Szolar  
Manfred Tillich  
Klaus W. Preidler

## Multi-detector CT urography: effect of oral hydration and contrast medium volume on renal parenchymal enhancement and urinary tract opacification—a quantitative and qualitative analysis

Received: 23 November 2009  
Revised: 25 January 2010  
Accepted: 28 February 2010  
© European Society of Radiology 2010

**Abstract** *Objective* To assess the effect of oral hydration and contrast-medium volume on renal enhancement and urinary tract opacification in multi-detector CT urography. *Methods* A total of 192 patients were assigned to different protocols with varying doses of contrast agent with and without oral hydration. The attenuation was measured in the renal parenchyma in the unenhanced, nephrographic and excretory phase, and in the urinary tract in excretory phase imaging, respectively. Opacification of the urinary tract was graded on volume rendered images. *Results* Oral hydration did not significantly alter renal parenchymal enhancement in both the nephrographic and the excretory phase ( $p > 0.001$ ), but significantly decreased mean attenuation of the urinary tract in the excretory phase ( $p \leq 0.001$ ), and improved con-

tinuous opacification of all ureter segments ( $p < 0.01$ ). Higher volumes of contrast medium improved renal parenchymal enhancement ( $p \leq 0.001$ ) and continuous opacification of the urinary tract ( $p \leq 0.01$ ). *Conclusion* Oral hydration leads to lower attenuation values in the urinary tract but improves the continuous opacification of the tract. Increase in contrast medium volume leads to higher renal parenchymal enhancement as well as to an increased continuous opacification of the urinary tract. Decrease in contrast medium volume cannot be compensated for by oral hydration in terms of parenchymal enhancement.

**Keywords** Computed tomography · CT urography · CT contrast material · CT kidneys · CT urinary tract

D. H. Szolar (✉) · M. Tillich ·  
K. W. Preidler  
Diagnostikum Graz-Südwest,  
Weblinger Gürtel 25, 8054 Graz, Austria  
e-mail: ds@diagnostikum-graz.at  
Tel.: +43-316-2477  
Fax: +43-316-247724

### Introduction

Multi-detector computed tomographic (CT) urography has become the “gold standard” and first-line technique in patients with urinary tract diseases for whom radiologic imaging is recommended. Despite the full acceptance of CT urography, there exists no universally accepted approach to performing it. To date, there have been some data available that focus on different strategies to optimise the diagnostic performance of multi-detector CT urography [2–5, 7, 10, 11, 13, 16]. For instance, Caoili and co-workers have demonstrated that both intravenous (IV) bolus infusion of 250 ml saline 15 min before CT and longer imaging delays (i.e. 450 s after intravenous

administration of contrast medium) are effective in improving opacification and visualisation of the urinary tract, while abdominal compression does not significantly improve distension and/or opacification of the urinary tract [3]. Other studies have demonstrated that IV administration of furosemide and/or prone positioning can optimise opacification of the renal collecting system and ureters, respectively [13]. More recently, only one study has qualitatively assessed the opacification of the urinary tract using oral water as a contrast medium [8].

However, there still exists a lack of detailed quantitative information on the effect of oral hydration on attenuation and enhancement of both the kidneys and the urinary tract in patients receiving different doses of contrast medium. There

are two questions that have to be raised: (1) do we need the same amount of contrast medium in patients undergoing multi-detector-row CT urography compared with conventional intravenous urography (IVU), and (2) does oral hydration substantially affect attenuation, enhancement and opacification of the kidneys or the urinary tract?

Therefore, this study was performed to prospectively compare different volumes of IV administered contrast medium in patients with or without oral hydration at multi-detector CT urography using time-optimised, delayed excretory phase image acquisition.

## Materials and methods

### Patients

Between August 2005 and July 2007, 192 consecutive outpatients (102 men and 90 women; mean age, 54 years; range, 19–88 years; mean weight, 80 kg; range, 52–135 kg) who underwent multi-detector CT urography were enrolled in the study. Indication for CT urography was possible urinary tract disease in patients with refractory (>2 months) but otherwise asymptomatic microhaematuria. Patients who had undergone previous nephrectomy, patients with macrohaematuria, patients with clinical history of cardiac disease, patients with acute flank pain, and patients with postoperative follow-up of known urinary tract malignancy were not included in the study. Contraindications for CT urography were previous allergic reaction to iodinated contrast medium, renal insufficiency, hyperthyreosis, pregnancy, and age under 18 years. All patients provided informed consent to the procedure. The weight of each patient was recorded and each patient was allocated to one of eight different study protocols. Each protocol consisted of 24 patients. The baseline demographic data are displayed in Table 1.

### Imaging

Studies were performed on a Somatom Sensation 64 Cardiac CT (Siemens, Erlangen, Germany). Patients had a standardised multi-detector CT urographic procedure with images obtained during unenhanced, nephrographic and

excretory phases. The unenhanced images were obtained through the abdomen and pelvis at  $24 \times 1.4$ -mm collimation (pitch of 1.4), 2.0-mm slice thickness and 2.0-mm reconstruction interval using a low-dose protocol (care dose 4d). Nephrographic phase images were obtained 100 s after the initiation of an intravenous injection of low-osmolality non-ionic contrast medium (iopentol 300; Imagopaque, General Electrics, London, England) administered at 3 ml/s with a power injector (MCT Plus; Medrad, Pittsburgh, Pa., USA). Nephrographic images were obtained from the diaphragm through the kidneys using  $64 \times 0.4$ -mm collimation (pitch 1.4) and were reconstructed at 2-mm section thickness and 2-mm reconstruction interval. Excretory phase images were obtained from the top of the kidneys to the base of the bladder with a 480-s delay employing the identical parameters to those used in the nephrographic phase. The time window of 480 s delay was found to be ideal based on the findings of a recently published study [8]. All imaging examinations were performed at 120 kVp and 40–160 mAs. Standard abdominal window settings (window width: 400; window centre: 40; kernel: B 30f medium smooth) were used in all scans. A standard algorithm was used for image display. Three-dimensional reconstructions of the excretory phase images were created at independent workstations (Wizard or Leonardo, Siemens Medical Solutions) by CT technologists.

### Image and data analysis

Image interpretation and attenuation measurements were performed retrospectively with a commercially available Sparc 10 CT/MR workstation (Siemens Sienet Magic View 1100; Erlangen, Germany) by two radiologists, each with more than 15 years CT experience, and more than 10 years' multi-detector experience. Both reviewers were blinded to the imaging procedure used in each patient. Transverse images were used for attenuation measurements. Measurements in the renal parenchyma were performed on unenhanced images, nephrographic phase images and excretory phase images using circular region-of-interest cursors; measurements in the renal collecting system and in the ureter were performed on the nephrographic phase images. The region-of-interest circle was kept constant in each patient for all measurements. The diameter of the region-of-interest circle used for measurements of attenuation of the renal collecting system and the ureter was maximised to the diameter of the area of interest without including edges. Every attempt was made to align the regions of interest on all the images and to maintain the largest region-of-interest area as anatomy allows in the transverse section. Care was also taken to exclude non-opacified areas (i.e. peripelvic fat tissue) and pathological lesions from the region of measurement. The contrast enhancement of the renal parenchyma during the nephrographic phase and excretory phase was calculated for each patient as the difference in attenuation values between the contrast-enhanced and unenhanced images.

**Table 1** Baseline demographic data for each study group

Group	No. of patients	Male/female	Mean age (years), range	Mean weight (kg), range
1	24	7/17	54 (22–78)	80 (55–111)
2	24	12/12	54 (20–71)	79 (52–117)
3	24	13/11	51 (21–82)	80 (52–108)
4	24	14/10	53 (19–77)	82 (60–120)
5	24	11/13	53 (21–88)	80 (52–110)
6	24	12/12	54 (20–77)	81 (60–110)
7	24	15/9	56 (25–79)	80 (55–135)
8	42	18/6	58 (23–75)	80 (55–110)

To qualitatively evaluate the opacification of the urinary tract, three-dimensional maximum-intensity projections and volume-rendered images were independently analysed by the same two radiologists. The urinary tract was divided into the renal collecting system, proximal ureter, middle ureter and distal ureter and these sections were defined as follows: the proximal ureter extended from the ureteropelvic junction to the lower pole of the ipsilateral kidney, the middle segment was located between the lower pole of the ipsilateral kidney and the ipsilateral crossing of the ureter with the iliac vessels, and the pelvic segment extended from the iliac vessels to the ureterovesical junction. For each segment, opacification was graded from 0 to 3 by using a scoring system. A score of 0 indicated no opacification of the segment; a score of 1, less than 50% opacification; a score of 2, 51–75% opacification; and a score of 3, 76–100% opacification. A discrepancy in the score of more than 1 between the two reviewers resulted in a review of images for a consensus score. Consensus was needed in 2.3% (36 out of 1,536) of scores.

#### Statistical analysis

For descriptive analyses of the data in each group the mean and standard deviation are used in the case of continuous variables, absolute and relative frequency for qualitative variables. The demographic variables age and weight were analysed using one-way ANOVA. To determine mean differences in objective region-of-interest measurements of attenuation between the different phase images of the kidneys paired *t*-tests were used for analysis for each group. The *p* values were adjusted for multiple comparisons using Bonferroni correction. Two-way ANOVA and post hoc tests were used to assess the effect on oral hydration and different doses of contrast material on renal and urinary tract attenuation. A *p* value less than 0.001 was considered to indicate a statistically significant difference. Opacification scores were analysed by Mann-Whitney *U*-test and Kruskal-Wallis test. All statistical analyses were performed with the statistical software package SPSS 16.0.

## Results

Baseline characteristics such as age, sex and weight did not differ significantly among the eight study groups ( $p > 0.05$ ) (Table 1). No adverse reaction to contrast medium occurred.

#### Renal parenchymal enhancement and attenuation of the urinary tract

The mean attenuations [ $\pm$  standard deviation (SD)] of the renal parenchyma in the unenhanced, nephrographic and

excretory phase for each group are listed in Table 2. For each group, the mean enhancement values of the renal parenchyma were significantly higher in the nephrographic phase than in the excretory phase ( $p \leq 0.001$ ) (Table 3). In the nephrographic phase, the enhancement was significantly different among the groups ( $p \leq 0.001$ ). Increasing the contrast medium volume by 20 ml or more led to a significant increase in the renal parenchyma ( $p \leq 0.001$ ), except the increase from 80 ml to 100 ml. Hydration did not influence parenchymal enhancement in the nephrographic phase ( $p > 0.001$ ) (Fig. 1a). In the excretory phase, contrast medium volume significantly influenced parenchymal attenuation. Increasing the contrast medium volume by 20 ml or more led to a significant increase in the renal parenchyma ( $p \leq 0.001$ ), except the increase from 80 ml to 100 ml. Oral hydration did not influence parenchymal enhancement in the nephrographic phase (Fig. 1b).

The mean attenuations ( $\pm$  SD) of the urinary tract in the excretory phase for each group are shown in Table 4. Mean attenuation values of both the renal collecting system and the ureter were significantly higher in the non-hydrated groups than in the hydrated groups ( $p < 0.001$ ). Contrast medium volume did not significantly influence the mean attenuation of the urinary tract (Fig. 2)

#### Opacification score of the urinary tract

The opacification scores of the urinary tract in the excretory phase are provided in Table 5. Although significantly lower attenuation values were measured in the urinary tract in the hydrated groups than in the non-hydrated groups, oral hydration improved the continuous opacification of the urinary tract. The improvement in opacification by hydration was statistically significant for all three ureter segments ( $p < 0.01$ ) but only showed a trend towards improved opacification in the renal collecting system ( $p = 0.036$ ).

Contrast medium volume significantly influenced opacification scores of the urinary tract ( $p \leq 0.01$ ), except the opacification score in the middle ureter which only showed a trend towards improved opacification ( $p = 0.037$ ). The higher the contrast medium dose given, the higher the score, independent of the hydration state of the patient (Fig. 3).

**Table 2** Attenuation measurements in renal parenchyma for each study group

Group	Mean attenuation $\pm$ SD (HU)		
	Unenhanced	Nephrographic phase	Excretory phase
1	38 $\pm$ 6	127 $\pm$ 22	85 $\pm$ 11
2	37 $\pm$ 3	118 $\pm$ 18	90 $\pm$ 9
3	37 $\pm$ 9	144 $\pm$ 26	99 $\pm$ 21
4	35 $\pm$ 6	152 $\pm$ 26	107 $\pm$ 22
5	37 $\pm$ 6	152 $\pm$ 26	107 $\pm$ 22
6	35 $\pm$ 7	145 $\pm$ 25	101 $\pm$ 18
7	35 $\pm$ 8	172 $\pm$ 25	114 $\pm$ 19
8	33 $\pm$ 4	163 $\pm$ 25	114 $\pm$ 18

**Table 3** Renal parenchymal enhancement

Group	Mean enhancement $\pm$ SD (HU)	
	Nephrographic phase	Excretory phase
1	85 $\pm$ 22	45 $\pm$ 11
2	74 $\pm$ 18	48 $\pm$ 9
3	106 $\pm$ 28	65 $\pm$ 23
4	91 $\pm$ 22	62 $\pm$ 17
5	115 $\pm$ 27	70 $\pm$ 22
6	111 $\pm$ 26	67 $\pm$ 20
7	138 $\pm$ 25	79 $\pm$ 20
8	129 $\pm$ 24	81 $\pm$ 19

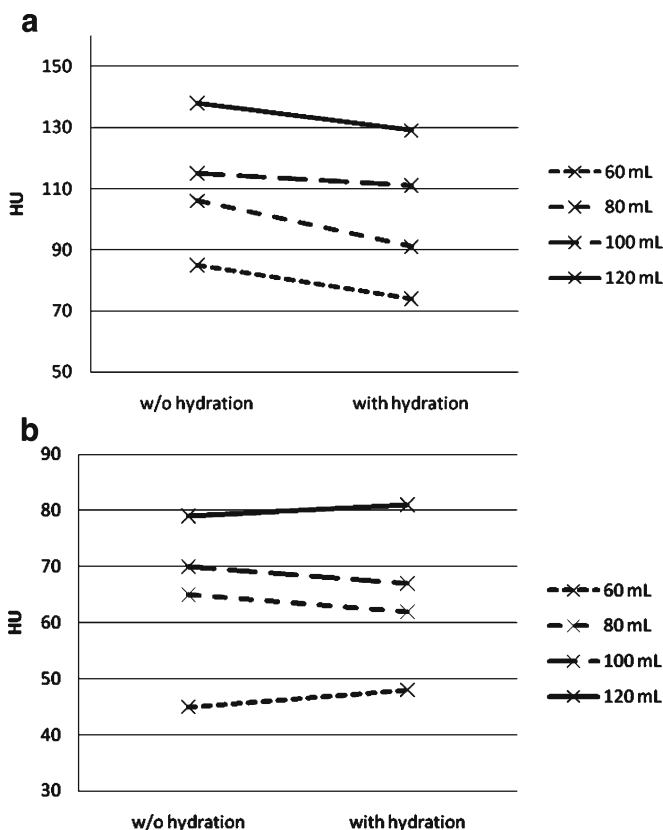
## Discussion

Multi-detector CT urography has become the gold standard in the evaluation of patients with refractory, otherwise asymptomatic haematuria [15, 17, 18]. Several imaging approaches have been used to optimise image quality, and hence, improve diagnostic accuracy [2–5, 7, 8, 10, 11, 13, 16]. Controversial opinions exist about the usefulness of adding saline to the contrast medium bolus with respect to achieving higher diagnostic accuracy. While a few studies have indicated that a supplemental saline bolus did not

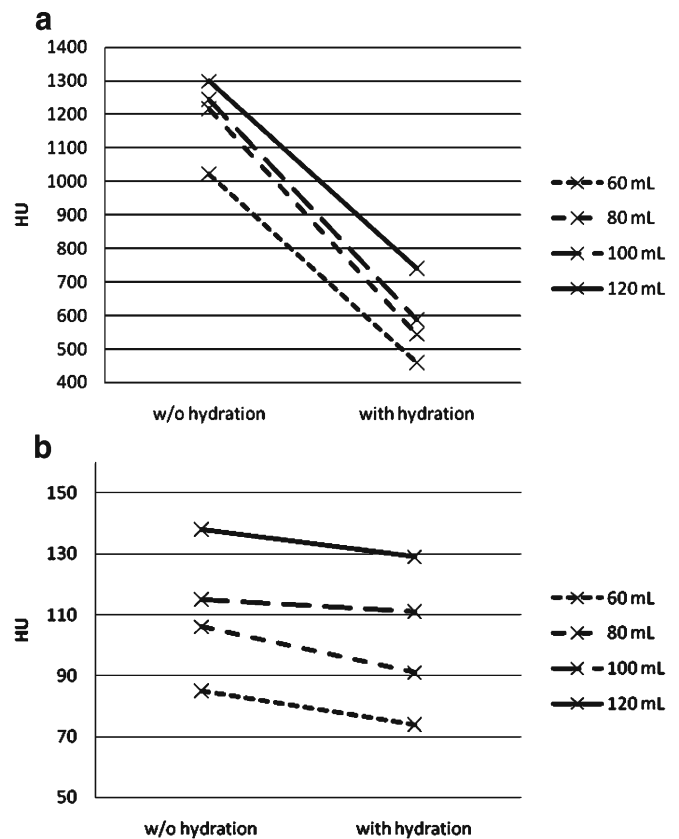
**Table 4** Attenuation measurements in renal collecting system and ureter during the excretory phase for each study group

Group	Mean attenuation $\pm$ SD (HU)	
	Renal collecting system	Ureter
1	1,023 $\pm$ 570	1,013 $\pm$ 565
2	460 $\pm$ 245	400 $\pm$ 160
3	1,216 $\pm$ 543	1,207 $\pm$ 591
4	544 $\pm$ 350	532 $\pm$ 394
5	1,244 $\pm$ 510	1,225 $\pm$ 480
6	587 $\pm$ 278	594 $\pm$ 303
7	1,299 $\pm$ 492	1,225 $\pm$ 468
8	740 $\pm$ 303	677 $\pm$ 271

offer diagnostic benefit or may improve evaluation of the urinary tract system [9, 16], Caoili et al. [3] have found that additional intravenous application of 250 ml saline significantly improved opacification and overall image quality of the renal collecting system and proximal ureter. Contrary to the present study, where oral intake of water also significantly improved middle and distal ureteral opacification, Caoili et al. [3] did not obtain significant results for these segments. McTavish et al. [11], however, found significant improvement in opacification only in the



**Fig. 1** **a** Renal parenchymal enhancement during the nephrographic phase without and with oral hydration for different volumes of IV contrast medium. **b** Renal parenchymal enhancement during the excretory phase without and with oral hydration for different volumes of IV contrast medium. In both cases, note that oral hydration did not influence parenchymal enhancement ( $p > 0.001$ ), whereas the amount of IV contrast medium did ( $p < 0.001$ )



**Fig. 2** **a** Attenuation of the renal collecting systems during the excretory phase without and with oral hydration for different volumes of IV contrast medium. **b** Attenuation of the ureters during the excretory phase without and with oral hydration for different volumes of IV contrast medium. In both cases, note that oral hydration significantly influenced attenuation ( $p < 0.001$ ), whereas the amount of IV contrast medium did not ( $p > 0.001$ )

**Table 5** Opacification score of the urinary tract

Group	Mean attenuation $\pm$ SD (HU)			
	Renal collecting system	Proximal ureter	Middle ureter	Distal ureter
1	2.30 $\pm$ 0.47	2.17 $\pm$ 0.39	1.83 $\pm$ 0.49	1.35 $\pm$ 0.71
2	2.42 $\pm$ 0.50	2.48 $\pm$ 0.49	2.29 $\pm$ 0.69	1.88 $\pm$ 0.74
3	2.38 $\pm$ 0.49	2.33 $\pm$ 0.48	2.25 $\pm$ 0.68	1.63 $\pm$ 0.65
4	2.58 $\pm$ 0.50	2.54 $\pm$ 0.51	2.21 $\pm$ 0.66	2.00 $\pm$ 0.72
5	2.54 $\pm$ 0.51	2.46 $\pm$ 0.51	2.17 $\pm$ 0.64	1.67 $\pm$ 0.70
6	2.67 $\pm$ 0.48	2.67 $\pm$ 0.48	2.50 $\pm$ 0.59	2.38 $\pm$ 0.71
7	2.63 $\pm$ 0.49	2.54 $\pm$ 0.51	2.29 $\pm$ 0.55	1.92 $\pm$ 0.83
8	2.79 $\pm$ 0.41	2.79 $\pm$ 0.41	2.58 $\pm$ 0.50	2.50 $\pm$ 0.59

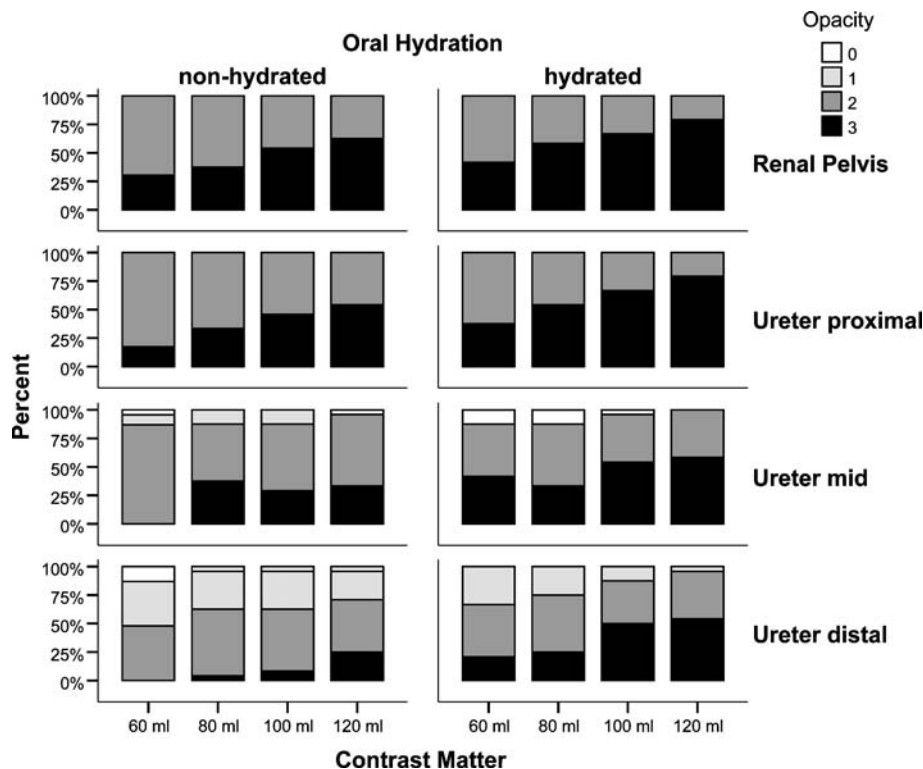
distal ureter in patients who underwent prone CT urography with a 250-ml infusion of normal saline immediately after the administration of contrast material. Maher and co-workers [9] showed that 100 ml of normal saline administered after contrast medium injection did not improve opacification of the urinary tract. These findings might be attributed to the lower volume of saline given, although another study concluded that the addition of a 250-ml saline bolus offered no improvement in collecting system opacification [16].

Currently, only one study has been published that has focused on the opacification of the urinary tract using oral water as contrast material [8]. Kawamoto and co-workers [8] found that one-quarter to one-third of lower ureters were not completely opacified. However, their study is hampered by several limitations, as no quantitative evaluation of the kidneys and the urinary tract was performed and, more crucially, no comparisons with

non-hydrated patients were done in order to demonstrate the effect of oral hydration on attenuation or enhancement of the kidneys and the urinary tract. Contrary to Kawamoto et al. [8], we included non-hydrated patients to allow for comparison with hydrated patients and, therefore, to evaluate the effect of hydration. The argument that oral hydration may have disadvantageous effects on diagnostic accuracy by decreasing the density of the contrast-enhanced urine may hold for conventional intravenous urography but not for CT urography. Far from it, dilution of the excreted contrast medium may reduce streak artefacts, thereby increasing diagnostic confidence. Furthermore, oral hydration reduces the reabsorption of water in the tubuli and, therefore, results in stronger diluting of the contrast material and reducing its potential nephrotoxicity [1, 15].

Interestingly, oral hydration did not influence renal parenchymal enhancement on both nephrographic and excretory phase images. Even at low doses of IV administered contrast medium, no significant differences between the hydrated and the non-hydrated groups were observed in the present study. Contrary to oral hydration, contrast medium dose did significantly influence renal parenchymal enhancement in the nephrographic and excretory phases as well. The question of whether a lower amount of contrast medium—e.g. equivalent to a dose given in conventional urography studies—can be given in patients undergoing CT urography may be of particular interest. The main consideration is that with respect to the technical advantages of multi-detector CT as a multiplanar imaging technique compared with the projectional imaging technique of conventional urography a smaller amount

**Fig. 3** Opacification score (0–3) of the renal pelvis and the ureters during the excretory phase without and with oral hydration for different volumes of IV contrast medium. Oral hydration led to significantly higher scoring in the ureter ( $p < 0.01$ ), whereas in the renal pelvis there was only a trend towards higher scoring with hydration



of contrast medium can be applied. In the era of intravenous urography, Hattery and coworkers have stated in their "How I do it" article on "Intravenous urographic technique" [6] that when a low-osmolality or non-ionic contrast agent is employed, 15–18 g of iodine should be given as a bolus injection. This is substantially less than the simple and modified dose rule of IV administered contrast medium—1 ml contrast medium per kg body weight—which has been used across the country as a bolus injection most often over the last few decades. However, both approaches use substantially less contrast medium compared with the currently widely accepted dose for CT urography of, for example, 36 g iodine (120 ml contrast medium with 300 mgI/ml) when using a low-osmolality, non-ionic contrast medium. However, the results of the present study indicate that, related to a special amount of parenchymal enhancement, a reduction of intravenous contrast medium cannot be compensated for by oral hydration. In addition, reduction of contrast medium volume led to a higher number of poorly opacified middle and distal ureter segments. Further studies including patients with renal conditions are necessary to evaluate whether the parenchymal enhancement achieved with low contrast medium doses (e.g. 18–24 g of contrast medium) is sufficient for detection of those conditions.

A general limitation of CT urography is the radiation dose, which is approximately 1.5-times higher than the radiation dose of conventional urography [12]. Several factors may influence the radiation dose, including the CT and IVU protocols used for comparison, patient size, CT type, use of dose modulation, and how radiation is measured or estimated. Following the concept of ALARA (as low as reasonably achievable), the study was conducted on a new CT type employing dose modulation software and all unenhanced images were obtained using a

low-dose protocol. A further reduction of the radiation dose may be achieved with use of the currently introduced split-bolus technique, which yields comparable high sensitivity and specificity values and substantially reduces the radiation dose and the number of images generated [14, 15].

A limitation of this study is that all patients were investigated in the supine position and comparisons with prone-positioned patients cannot be derived. However, most of the published series on CT urography have investigated their patients in the supine position, although one study addresses the value of prone positioning to improve opacification of the urinary tract, but reached statistical significance only for the mid-ureter [10]. In spite of conflicting and equivocal supporting evidence, we routinely employ supine positioning for CT urography. Both the non-use of compression techniques and the non-use of intravenous furosemide were not considered to be limitations. Compression devices are often ineffective and cumbersome, necessitate imaging the upper and lower tracts separately, and are contraindicated in specified patients [3–5, 7]. Although the administration of intravenous furosemide is considered to be safe, we refrained from its use on our outpatients because it is a drug with certain contraindications.

In summary, the results of the present study indicate that oral hydration with intake of 1,000 ml water 30–45 min before CT urography leads to lower attenuation values in the urinary tract but improves the continuous opacification of the tract. Increases in contrast medium volume lead to higher renal parenchymal enhancement in the nephrographic and excretory phases and to increased continuous opacification of the urinary tract as well. Decreases in contrast medium volume cannot be compensated for by oral hydration in terms of parenchymal enhancement.

## References

1. Akbar S, Mortele K, Baeyens K, Kekelidze M, Silverman S (2004) Multidetector CT urography: techniques, clinical applications, and pitfalls. *Semin Ultrasound CT MR* 25:41–54
2. Caoili E, Cohan R, Korobkin M et al (2002) Urinary tract abnormalities: initial experience with multi-detector row CT urography. *Radiology* 222:353–360
3. Caoili E, Inampudi P, Cohan R, Ellis J (2005) Optimization of multi-detector row CT urography: effect of compression, saline administration, and prolongation of acquisition delay. *Radiology* 235:116–123
4. Caoili EM, Cohan RH, Korobkin M et al (2001) Effectiveness of abdominal compression during helical renal CT. *Academ Radiol* 8:1100–1106
5. Chow LC, Sommer FG (2001) Multidetector CT urography with abdominal compression and three-dimensional reconstruction. *AJR Am J Roentgenol* 177:849–855
6. Hattery RR, Williamson B, Hartman GW, LeRoy AJ, Witten DM (1988) Intravenous urographic technique. *Radiology* 167:593–599
7. Heneghan JP, Kim DH, Leder RA, DeLong D, Nelson RC (2001) Compression CT urography: a comparison with IVU in the opacification of the collecting system and ureters. *J Comput Assist Tomogr* 25:343–347
8. Kawamoto S, Horton K, Fishman E (2006) Opacification of the collecting system and ureters on excretory-phase CT using oral water as contrast medium. *AJR Am J Roentgenol* 186:136–140
9. Maher MM JK, Lucey BC, Sahani DV, Saini S, Mueller PR (2001) Does the administration of saline flush during CT urography improve ureteric distension and opacification? A prospective study. *Radiology* 221(Suppl P):500
10. McNicholas MM, Raptopoulos VD, Schwartz RK et al (1998) Excretory phase CT urography for opacification of the urinary collecting system. *AJR Am J Roentgenol* 170:1261–1267

- 
11. McTavish J, Jinzaki M, Zou K, Nawfel R, Silverman S (2002) Multi-detector row CT urography: comparison of strategies for depicting the normal urinary collecting system. *Radiology* 225:783–790
  12. Nawfel R, Judy P, Schleipman AR, Silverman S (2004) Patient radiation dose at CT urography and conventional urography. *Radiology* 232:126–132
  13. Nolte-Ernsting CC, Wildberger JE, Borchers H, Schmitz-Rode T, Gnther RW (2001) Multi-slice CT urography after diuretic injection: initial results. *RöFo* 173:176–180
  14. Sadow CA SS (2007) CT urography in patients 40years old or younger: is it worth it? In: Abstracts of the Radiological Society of North America Scientific Assembly and Annual Meeting Program. Radiological Society of North America, Oak Brook, p 300
  15. Silverman S, Leyendecker J, Amis ES (2009) What is the current role of CT urography and MR urography in the evaluation of the urinary tract? *Radiology* 250:309–323
  16. Sudakoff G, Dunn D, Hellman R et al (2006) Opacification of the genitourinary collecting system during MDCT urography with enhanced CT digital radiography: nonsaline versus saline bolus. *AJR Am J Roentgenol* 186:122–129
  17. O'Connor OJ, McSweeney SE, Maher MM (2008) Imaging of hematuria. *Radiol Clin N Am* 46:113–132
  18. Nolte-Ernsting C, Cowan N (2006) Understanding multislice CT urography techniques: many roads lead to Rome. *Eur Radiol* 16:2670–2686